

# Case discussion – Southern African HIV Clinicians Society Conference 2014

---

Colin Menezes

Division of Infectious Diseases

Department of Internal Medicine

Chris Hani Baragwanath Academic Hospital

University of the Witwatersrand

# History

---

- A 28 year old HIV +ve female presented with 3 month history of painful and progressive swelling of her right ankle and knee, followed by her left ankle and elbow in August 2014. Nil other symptoms apart from skin lesions on her face, trunk and thighs.
- She had been diagnosed with HIV-infection (CD4 count 15 cells/ $\mu$ L) and started on TDF/3TC/EFV in July 2013 after being treated for cryptococcal meningitis in June 2013.
- Her prophylactic fluconazole was stopped in April 2014 at the local ARV clinic.

# Question 1:

---

- Was stopping her fluconazole justified?

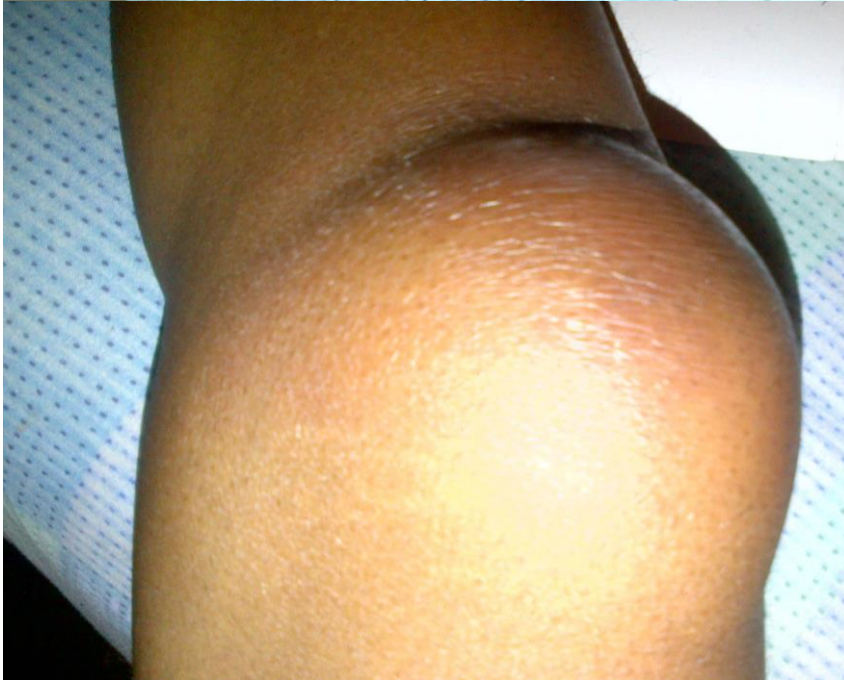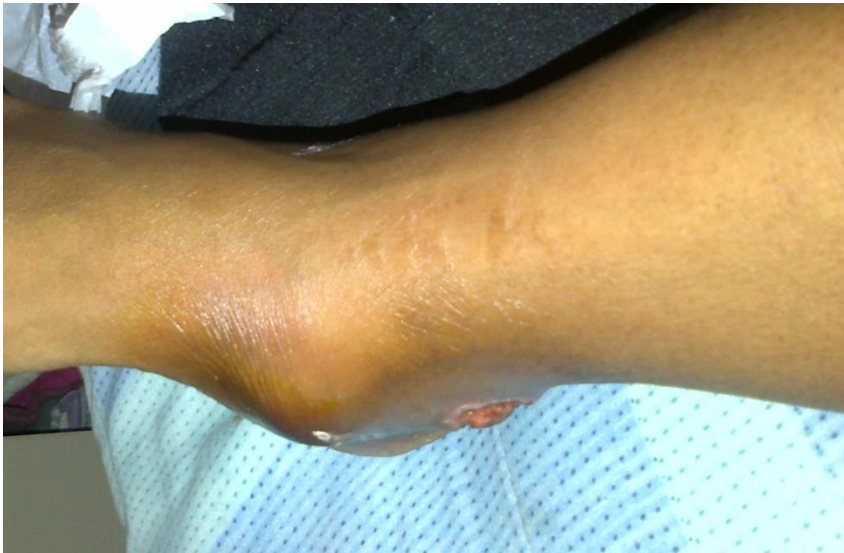A) Yes

B) No

# On examination

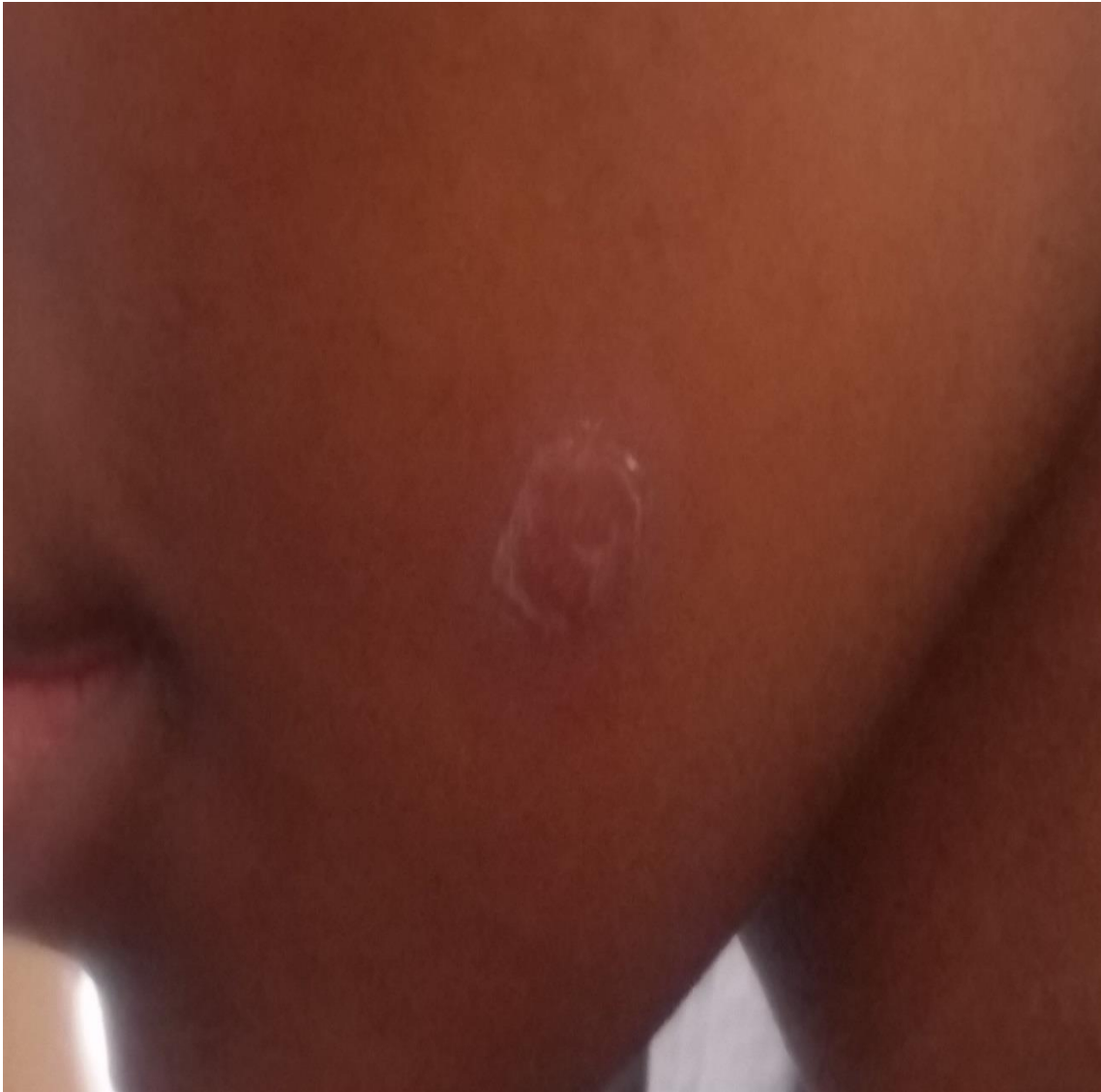---

- Was found to have swollen, warm and fluctuant ankles, right knee and left elbow, with pus oozing from the right ankle.
- She had no neck stiffness, and the remainder of her clinical examination was normal.



# On examination

---



- She had well circumscribed, scaling plaques on her face, trunk and thighs.

# Question 2:

---

What is the likely diagnosis?

- A) Pyogenic oligoarthritis
- B) Reactive arthritis
- C) Fungal oligoarthritis
- D) Mycobacterial oligoarthritis

# Question 3:

---

What diagnostic tests would you do?

A) X-rays of the joints and chest

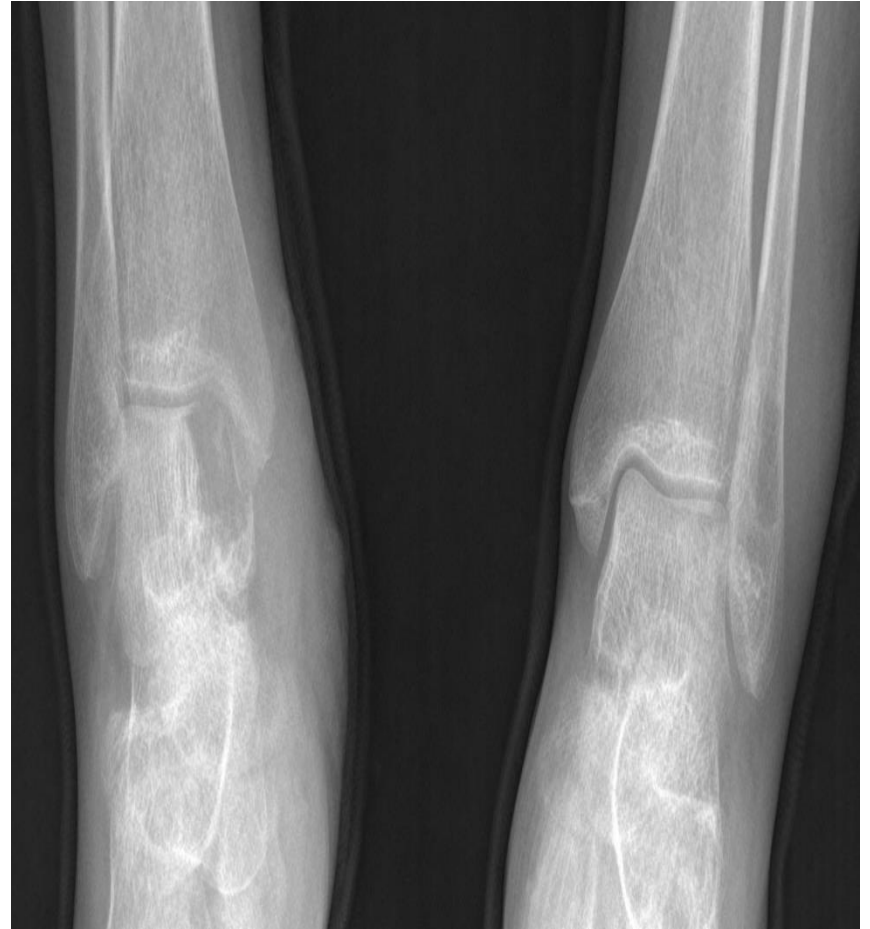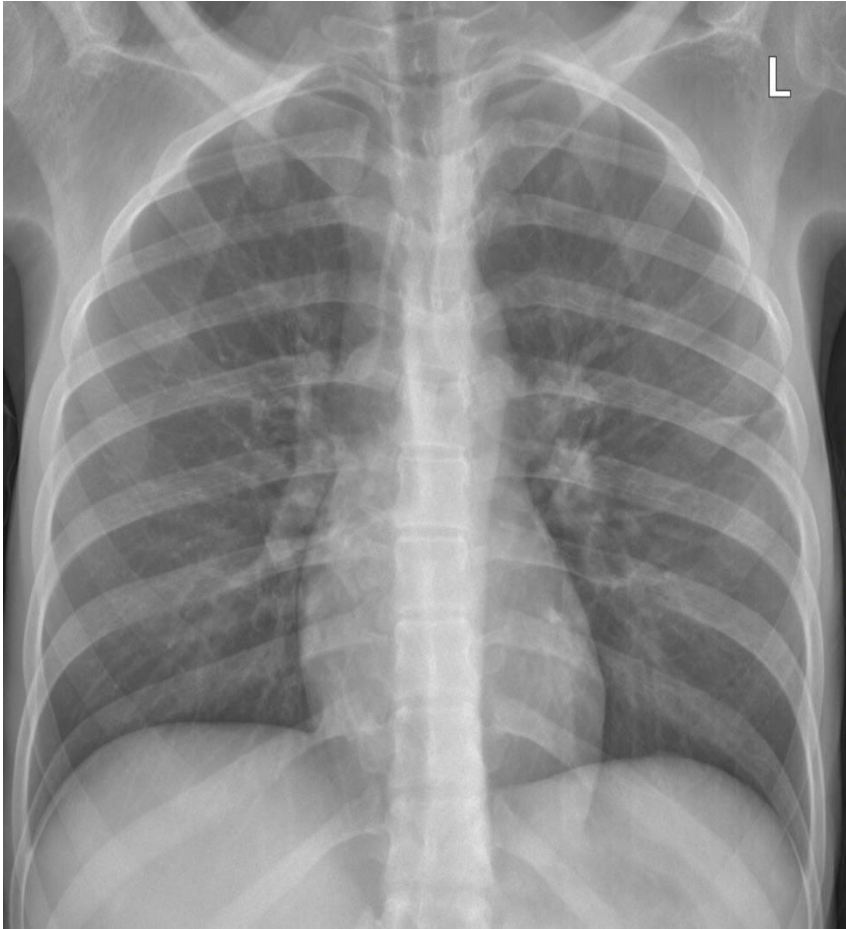
B) Blood cultures

C) Joint aspirates for MC & S, and TB culture

D) All of the above

# X-rays

---





# Results

---

- Bloods: FBC, U+E, Serum CrAg, CD4 count (168 cells/ $\mu$ L), VL (LDL).
- Pus aspirate cell count: polymorphs 10000 /uL, lymphocytes 500 /uL, erythrocytes >10000 /uL. Crystals not observed.
- Lumber puncture.

# Question 4:

---

- What would you suggest as therapy for this patient ?

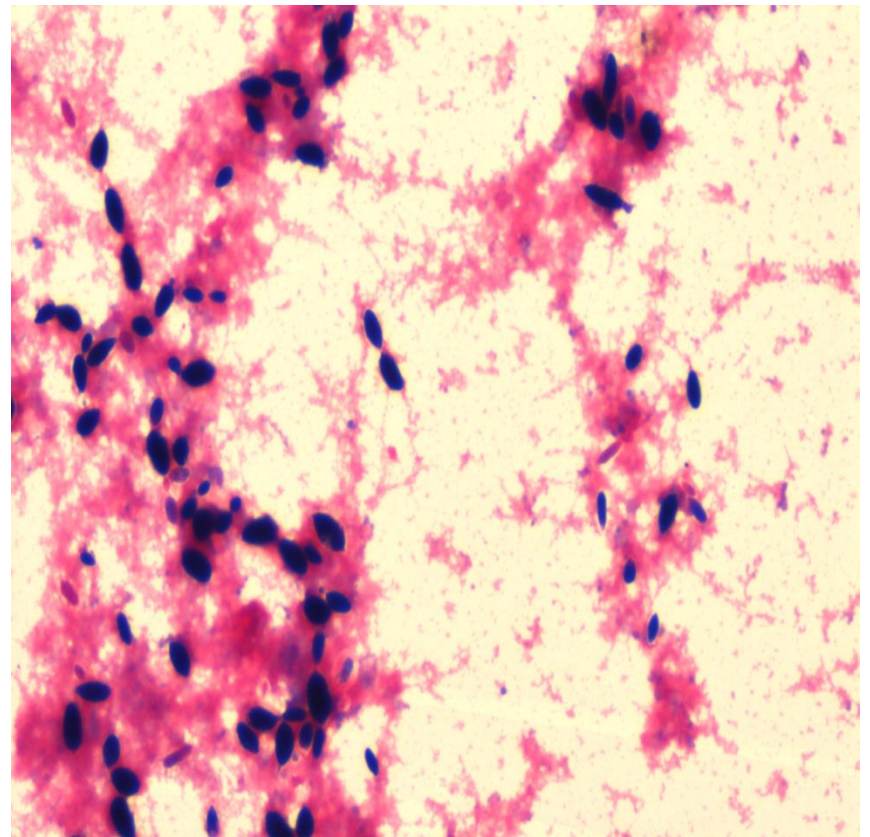
# Microbiology

---

## Cultures

- Joint aspirate
- Blood cultures
- Pus swab

## Grams stain of blood culture



# Histology

---

- Had a right ankle and knee arthrotomy, histology of knee confirmed presence of necrotizing granulomatous inflammation with fungal elements identified on Grocott staining.
- The histology of the skin biopsy was suggestive of molluscum contagiosum.

# Question 5:

---

- What would you do for this patient now in terms of therapy?

# Management:

---

- Provisionally labelled as disseminated cryptococcal infection manifesting as a oligoarthritis.
- Good response to IV amphotericin and oral fluconazole except for the right knee which needed a re-look by the orthopaedic surgeons.

# Question 6:

---

- Is this progression of disease?
- Is this relapse off fluconazole?
- Is this an immune reconstitution syndrome (IRIS)?

# Management

---

- 2 weeks into therapy – developed nosocomial sepsis and a right lower limb deep venous thrombosis and needed to be anti-coagulated.
- What are your concerns about her possible drug side effects and drug-drug interactions?



# One final result!

---

- Discharged after nearly one month in hospital for follow up as an outpatient.
- BUT now molecular identification reveals *Aureobasidium pullulans*.
- What you do next?

# Acknowledgement

---

- Dr G Mathole and the Medical team
- Prof A Karstaedt and the ID team
- Dr W Tulleken and the Rheum/Ortho team.
- Dr M Moodley and the CMID team.